

# Circulation

JOURNAL OF THE AMERICAN HEART ASSOCIATION



## Acute Pulmonary Embolism: Part I: Epidemiology and Diagnosis

Gregory Piazza and Samuel Z. Goldhaber

*Circulation* 2006;114:28-32

DOI: 10.1161/CIRCULATIONAHA.106.620872

Circulation is published by the American Heart Association, 7272 Greenville Avenue, Dallas, TX 75214

Copyright © 2006 American Heart Association. All rights reserved. Print ISSN: 0009-7322. Online ISSN: 1524-4539

The online version of this article, along with updated information and services, is located on the World Wide Web at:

<http://circ.ahajournals.org/cgi/content/full/114/2/e28>

Subscriptions: Information about subscribing to *Circulation* is online at  
<http://circ.ahajournals.org/subscriptions/>

Permissions: Permissions & Rights Desk, Lippincott Williams & Wilkins, 351 West Camden Street, Baltimore, MD 21202-2436. Phone 410-5280-4050. Fax: 410-528-8550. Email:  
[journalpermissions@lww.com](mailto:journalpermissions@lww.com)

Reprints: Information about reprints can be found online at  
<http://www.lww.com/static/html/reprints.html>

# Acute Pulmonary Embolism

## Part I: Epidemiology and Diagnosis

Gregory Piazza, MD; Samuel Z. Goldhaber, MD

**C**ase 1: A 54-year-old previously healthy woman presented to the emergency department with a history of several days of progressive dyspnea. She was taking combined estrogen-progestin therapy for symptoms of menopause. On the basis of elements of her history and physical examination, she was considered to have a moderate clinical likelihood of pulmonary embolism (PE). Her D-dimer level was elevated, and a chest computed tomography (CT) scan with contrast demonstrated a right main pulmonary artery embolus. What is the strongest clinical clue suggesting PE?

Case 2: A 71-year-old man receiving hormonal therapy for prostate cancer presented to the emergency department with acute-onset chest discomfort, dyspnea, and lower extremity edema. Laboratory studies revealed normal cardiac biomarkers. The only electrocardiographic abnormality was sinus tachycardia; the chest x-ray was normal. Chest CT with contrast revealed multiple bilateral pulmonary emboli. Lower extremity venous ultrasonography showed thrombus in the left femoral vein. Should a D-dimer

blood test have been ordered before the chest CT?

### Epidemiology

The incidence of venous thromboembolism (VTE), which includes PE and deep venous thrombosis (DVT), has remained relatively constant, with age- and sex-adjusted rates of 117 cases per 100 000 person-years.<sup>1</sup> VTE incidence rises sharply after age 60 in both men and women, with PE accounting for the majority of the increase.<sup>2</sup>

The mortality rate associated with PE is underappreciated; it exceeds 15% in the first 3 months after diagnosis.<sup>3</sup> In nearly 25% of patients with PE, the initial clinical manifestation is sudden death.<sup>1</sup>

### Risk Factors

Risk factors for VTE include various inherited disorders, as well as the acquired conditions of endothelial injury, stasis, and hypercoagulability (Table). The majority of patients present with a combination of risk factors.

### Inherited Conditions

Inherited thrombophilias are often suspected in patients with VTE at a young

age, multiple family members with VTE, idiopathic or recurrent VTE, or recurrent spontaneous abortions. Major inherited thrombophilias include factor V Leiden leading to activated protein C resistance, prothrombin gene mutation, and deficiencies of antithrombin III, protein C, or protein S. The prevalence of these inherited conditions varies by population.

### Acquired Conditions

Acquired risk factors for VTE are far more prevalent than inherited thrombophilias. Increasing age, smoking, obesity, personal or family history of VTE, and recent surgery, trauma, or hospitalization are well-established risk factors. Recently, acute infectious illnesses such as urinary tract infections have been associated with a transient increased risk of VTE in the community setting.<sup>4</sup> In addition to physical immobility, long-haul air travel appears to result in activation of coagulation and contributes to an increased risk of VTE.<sup>5</sup> Although established malignancy with or without concomitant chemotherapy is a well-recognized risk factor, occult malignancy is also associated with an in-

From the Division of Cardiology, Department of Medicine, Beth Israel Deaconess Medical Center (G.P.), and the Cardiovascular Division, Department of Medicine, Brigham and Women's Hospital (S.Z.G.), Harvard Medical School, Boston, Mass.

This article is Part I of a 2-part article. Part II will appear in the July 18, 2006, issue of *Circulation*.

Correspondence to Samuel Z. Goldhaber, MD, Cardiovascular Division, Brigham and Women's Hospital, 75 Francis St, Boston, MA 02115. E-mail [sgoldhaber@partners.org](mailto:sgoldhaber@partners.org)

(*Circulation*. 2006;114:e28-e32.)

© 2006 American Heart Association, Inc.

*Circulation* is available at <http://www.circulationaha.org>

DOI: 10.1161/CIRCULATIONAHA.106.620872

## Major Risk Factors for Venous Thromboembolism

### Inherited

- Factor V Leiden mutation
- Prothrombin gene mutation
- Deficiency of antithrombin III, protein C, or protein S

### Acquired

- Age
- Smoking
- Obesity
- Malignancy
- Antiphospholipid antibody syndrome
- Hyperhomocysteinemia (less commonly inherited secondary to a mutation in methylenetetrahydrofolate reductase)
- Oral contraceptive pills or hormone replacement therapy
- Atherosclerotic disease
- Personal or family history of venous thromboembolism
- Recent trauma, surgery, or hospitalization
- Acute infection
- Long-haul air travel
- Pacemaker or implantable cardiac defibrillator leads and indwelling venous catheters

creased incidence of VTE. The incidence of newly diagnosed cancer is significantly elevated for several years after a first episode of VTE.<sup>6</sup>

Antiphospholipid antibody syndrome is an acquired hypercoagulable state that increases the risk for both venous and arterial thromboembolism, as well as recurrent fetal loss.<sup>7</sup> Hyperhomocysteinemia is also associated with an increased incidence of arterial and venous thromboembolism.<sup>8</sup> Although it may be due to an inherited deficiency in methylenetetrahydrofolate reductase, hyperhomocysteinemia is most often caused by folate deficiency.<sup>8</sup>

The risk of VTE is an important women's health issue. In addition to the known increase in risk associated with pregnancy, the use of oral contraceptive pills, especially third generation formulations, has been associated with an elevated risk of VTE.<sup>9</sup> The Women's Health Initiative docu-

mented a 2-fold increase in the risk of VTE among women receiving estrogen plus progestin hormone replacement therapy compared with those receiving placebo.<sup>10</sup> Patients with evidence of atherosclerotic disease were found to have an increased incidence of VTE compared with control subjects.<sup>11</sup> Pacemaker and internal cardiac defibrillator leads and long-term indwelling venous catheters increase the risk of upper extremity DVT.<sup>12</sup>

## Evaluation of Hypercoagulability

Thrombophilia work-ups are generally reserved for patients in whom there is a high suspicion for a hypercoagulable state. The initial evaluation should emphasize the most common thrombophilias, which include factor V Leiden, prothrombin gene mutation, antiphospholipid antibody syndrome, and hyperhomocysteinemia. Subsequent testing may focus on less prevalent disorders, such as deficiencies of antithrombin III, protein C, and protein S.

## Pathophysiology

Pulmonary emboli most often arise from the deep veins of the lower extremity and pelvis. Thrombi dislodge from these veins and embolize to the pulmonary arteries, where they cause abnormalities in hemodynamics and gas exchange.

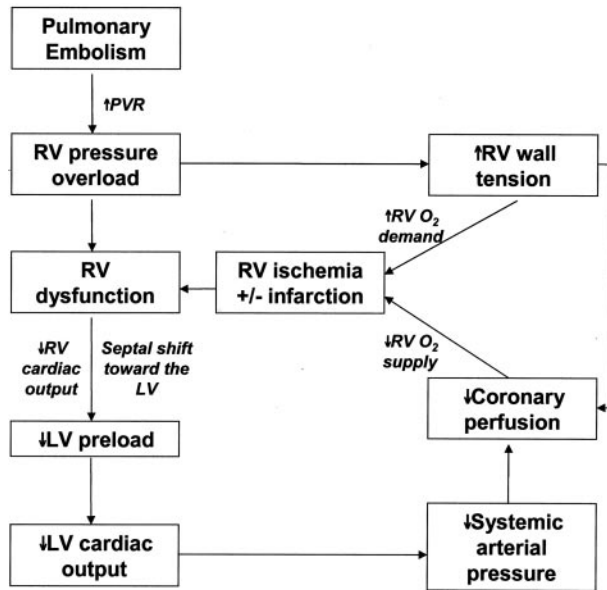
The hemodynamic response to PE is determined by the size of the embolus, the patient's underlying cardiopulmonary status, and compensatory neurohumoral adaptations.<sup>13</sup> In addition to physical obstruction, acute PE leads to the release of pulmonary artery vasoconstrictors and hypoxemia, with a subsequent increase in pulmonary vascular resistance and right ventricular (RV) afterload.<sup>13</sup> The abrupt increase in RV afterload can cause RV dilation and hypokinesis, tricuspid regurgitation, and ultimately RV failure.<sup>13</sup> Patients with RV failure may rapidly progress to systemic arterial hypotension and cardiac arrest. RV pressure overload can also lead to interventricular septal flattening and deviation toward the left ventricle (LV) in diastole,

thereby impairing LV filling.<sup>13</sup> This manifestation of interventricular dependence also leads to an alteration of normal transmitral flow with left atrial contraction, represented by the A wave on Doppler echocardiography, making a greater contribution to LV diastole than passive filling, represented by the E wave.<sup>13</sup> RV pressure overload also increases wall stress and leads to ischemia by increasing myocardial oxygen demand while limiting supply (Figure 1).<sup>13</sup>

Mechanisms leading to impaired gas exchange include ventilation-to-perfusion mismatch, increases in total dead space, and right-to-left shunting.<sup>13</sup> Arterial hypoxemia and an increased alveolar-arterial oxygen gradient are the 2 most common abnormalities of gas exchange.<sup>13</sup> Hyperventilation may contribute to hypocapnia and respiratory alkalosis.<sup>13</sup> The presence of hypercapnia suggests massive PE leading to increased anatomic and physiological dead space and impaired minute ventilation.<sup>13</sup>

## Diagnosis

The diagnosis of acute PE requires the integration of a careful history and physical examination with laboratory testing and appropriate imaging modalities. The clinical presentation of PE can vary widely from one patient to another. Dyspnea is the most frequent presenting symptom. Although severe dyspnea, cyanosis, or syncope suggests a massive PE, pleuritic pain, cough, or hemoptysis may indicate a smaller peripherally located PE. On physical examination, tachypnea is the most common sign. Of note, patients without underlying cardiopulmonary disease may appear anxious but otherwise well compensated despite an anatomically large PE. In contrast, patients with massive PE may present with hypotension, cardiogenic shock, or cardiac arrest. Patients with submassive PE fit between these 2 extremes. They have preserved systolic blood pressure but exhibit signs of RV failure, including tachycardia, distended neck veins, tricuspid regurgitation, and

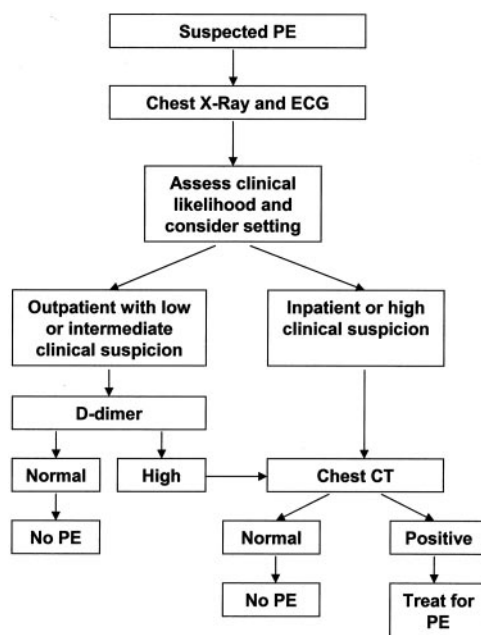


**Figure 1.** The pathophysiology of right ventricular dysfunction secondary to acute pulmonary embolism. PVR indicates pulmonary vascular resistance; O<sub>2</sub>, oxygen.

an accentuated sound of pulmonic closure (P2).

The laboratory evaluation of suspected PE should rely on the use of D-dimer testing in appropriately selected patients. A nonspecific marker of fibrinolysis, D-dimer, as measured by ELISA, offers a high sensitivity and

high negative predictive value and therefore has utility in the exclusion of PE, especially in the emergency room setting.<sup>14</sup> The D-dimer ELISA can be used to exclude PE in outpatients with a low to moderate suspicion without the need for further costly testing.<sup>15</sup> Inpatients should undergo an imaging



**Figure 2.** An integrated approach to the evaluation of patients with suspected pulmonary embolism.

study as the initial test for PE because most will already have elevated D-dimers secondary to comorbid conditions.

Electrocardiography may suggest alternative diagnoses such as myocardial infarction. In patients with PE, the ECG may reveal signs of RV strain, including incomplete or complete right bundle-branch block, T-wave inversions in the anterior precordium, and an S wave in lead I and a Q-wave and T-wave inversion in lead III (S1Q3T3). The ECG may be entirely normal in young, previously healthy patients.

The chest x-ray is often normal. Findings such as focal oligemia (Westermark sign), a peripheral wedge-shaped opacity (Hampton's hump), or an enlarged right descending pulmonary artery (Palla's sign) are rare.

Chest CT with intravenous contrast has become the principal diagnostic imaging modality to evaluate suspected PE. The replacement of single-detector scanners with newer multidetector CT scanners has increased the detection rate of subsegmental PE and has virtually eliminated nondiagnostic studies.<sup>16</sup> An overview of chest CT in the evaluation of suspected acute PE demonstrated negative predictive values of 99.1% and 99.4% for pulmonary embolism and mortality attributable to pulmonary embolism, respectively.<sup>17</sup> These data suggest that chest CT is at least as accurate as invasive pulmonary angiography.<sup>17</sup>

Alternative imaging modalities include ventilation-perfusion (V/Q) lung scanning, magnetic resonance (MR) angiography, transthoracic and transesophageal echocardiography (TTE and TEE, respectively), and invasive pulmonary angiography. V/Q scans are generally reserved for patients with major renal impairment, anaphylaxis to intravenous contrast, or pregnancy. MR angiography is a promising modality for detecting PE in the proximal pulmonary arteries and avoids the risks of iodinated contrast and ionizing radiation.

TTE is insensitive for diagnosis but plays an important role in risk stratification of patients with proven acute PE. TTE detects RV dysfunction in the setting of RV pressure overload. Echocardiographic findings among patients with PE include RV dilatation and hypokinesis, paradoxical interventricular septal motion toward the LV, tricuspid regurgitation, and pulmonary hypertension.<sup>18</sup> The finding of regional RV dysfunction with severe free wall hypokinesis sparing the apex (McConnell sign) is specific for PE.<sup>19</sup> Among normotensive patients with acute PE, RV hypokinesis is an independent risk predictor for early death.<sup>20</sup> In hemodynamically unstable patients, TTE can be performed rapidly and may reveal evidence of RV failure suggestive of PE, as well as other conditions including myocardial infarction, aortic dissection, and pericardial tamponade.<sup>21</sup> TEE provides direct visualization of the proximal pulmonary arteries.<sup>18</sup>

Invasive pulmonary angiography is used diagnostically in the rare circumstance when other imaging modalities are nondiagnostic and a high clinical suspicion for PE persists. Lower extremity venous ultrasonography revealing DVT may support a clinical diagnosis of PE when other imaging modalities are nondiagnostic.

An integrated diagnostic approach is essential (Figure 2). A prospective cohort study used an algorithm consisting of a dichotomized clinical decision rule, D-dimer testing, and chest CT to evaluate patients with suspected PE.<sup>22</sup> A modified version of the Wells clinical decision rule assigned 3 points for clinical signs and symptoms of DVT, 3 points for an alternative diagnosis less likely than PE, 1.5 points for a heart rate >100 beats per minute, 1.5 points for recent immobilization or surgery, 1.5 points for previous VTE, 1 point for hemoptysis, and 1 point for malignancy receiving treatment or palliative care within the last 6 months.<sup>22</sup> Patients with 4 or fewer points were categorized as “pulmonary embolism unlikely” and those with more than 4 points were classified as “pulmonary

embolism likely.”<sup>22</sup> Patients in the “pulmonary embolism likely” group proceeded directly to chest CT, whereas those in the “pulmonary embolism unlikely” category underwent D-dimer testing; only patients with abnormal D-dimers were referred for chest CT.<sup>22</sup> PE was considered to be excluded in patients categorized as “pulmonary embolism unlikely” with negative D-dimer results and in patients with negative chest CT scans.<sup>22</sup> Use of this simple algorithm permitted a management decision in 98% of patients and was associated with a low risk of VTE.<sup>22</sup>

### Cases 1 and 2

Case 1 demonstrates the increased risk of VTE with hormone replacement therapy in an outpatient without other known risk factors. The case also highlights the diagnostic approach of using D-dimer in conjunction with an assessment of clinical likelihood. The elevated D-dimer was appropriately followed with a chest CT that documented PE. The history of progressive, otherwise unexplained dyspnea is the strongest clinical clue.

Case 2 emphasizes malignancy as a potent risk factor for VTE. Standard tests to evaluate chest discomfort and dyspnea may be unrevealing. In this patient, the ECG only demonstrated sinus tachycardia and the chest x-ray was normal. The case also highlights the need to proceed directly to an imaging study in a patient with a high clinical likelihood of PE. Lower extremity ultrasonography revealed the most likely source of the PE: a left femoral DVT.

### Sources of Funding

Dr Goldhaber has received research grants from Sanofi Aventis and GlaxoSmithKline.

### Disclosures

Dr Goldhaber has served as a consultant to or on an advisory board for Sanofi Aventis. Dr Piazza reports no conflicts.

### References

1. Heit JA. The epidemiology of venous thromboembolism in the community: implications

- for prevention and management. *J Thromb Thrombolysis*. 2006;21:23–29.
2. Silverstein MD, Heit JA, Mohr DN, Petterson TM, O’Fallon WM, Melton LJ 3rd. Trends in the incidence of deep vein thrombosis and pulmonary embolism: a 25-year population-based study. *Arch Intern Med*. 1998;158:585–593.
3. Goldhaber SZ, Visani L, De Rosa M. Acute pulmonary embolism: clinical outcomes in the International Cooperative Pulmonary Embolism Registry (ICOPER). *Lancet*. 1999;353:1386–1389.
4. Smeeth L, Cook C, Thomas S, Hall AJ, Hubbard R, Vallance P. Risk of deep vein thrombosis and pulmonary embolism after acute infection in a community setting. *Lancet*. 2006;367:1075–1079.
5. Schreijer AJ, Cannegieter SC, Meijers JC, Middeldorp S, Buller HR, Rosendaal FR. Activation of coagulation system during air travel: a crossover study. *Lancet*. 2006;367:832–838.
6. Schulman S, Lindmarker P. Incidence of cancer after prophylaxis with warfarin against recurrent venous thromboembolism. Duration of Anticoagulation Trial. *N Engl J Med*. 2000;342:1953–1958.
7. Lim W, Crowther MA, Eikelboom JW. Management of antiphospholipid antibody syndrome: a systematic review. *JAMA*. 2006;295:1050–1057.
8. Hankey GJ, Eikelboom JW. Homocysteine and vascular disease. *Lancet*. 1999;354:407–413.
9. Vandembroucke JP, Rosing J, Bloemenkamp KW, Middeldorp S, Helmerhorst FM, Bouma BN, Rosendaal FR. Oral contraceptives and the risk of venous thrombosis. *N Engl J Med*. 2001;344:1527–1535.
10. Rossouw JE, Anderson GL, Prentice RL, LaCroix AZ, Kooperberg C, Stefanick ML, Jackson RD, Beresford SA, Howard BV, Johnson KC, Kotchen JM, Ockene J. Risks and benefits of estrogen plus progestin in healthy postmenopausal women: principal results From the Women’s Health Initiative randomized controlled trial. *JAMA*. 2002;288:321–333.
11. Prandoni P, Bilora F, Marchiori A, Bernardi E, Petrobelli F, Lensing AW, Prins MH, Girolami A. An association between atherosclerosis and venous thrombosis. *N Engl J Med*. 2003;348:1435–1441.
12. Joffe HV, Goldhaber SZ. Upper-extremity deep vein thrombosis. *Circulation*. 2002;106:1874–1880.
13. Goldhaber SZ, Elliott CG. Acute pulmonary embolism: part I: epidemiology, pathophysiology, and diagnosis. *Circulation*. 2003;108:2726–2729.
14. Dunn KL, Wolf JP, Dorfman DM, Fitzpatrick P, Baker JL, Goldhaber SZ. Normal D-dimer levels in emergency department patients suspected of acute pulmonary embolism. *J Am Coll Cardiol*. 2002;40:1475–1478.
15. Stein PD, Hull RD, Patel KC, Olson RE, Ghali WA, Brant R, Biel RK, Bharadia V, Kalra NK. D-dimer for the exclusion of acute venous thrombosis and pulmonary



- embolism: a systematic review. *Ann Intern Med.* 2004;140:589–602.
16. Schoepf UJ, Holzkecht N, Helmberger TK, Crispin A, Hong C, Becker CR, Reiser MF. Subsegmental pulmonary emboli: improved detection with thin-collimation multi-detector row spiral CT. *Radiology.* 2002; 222:483–490.
  17. Quiroz R, Kucher N, Zou KH, Kipfmueller F, Costello P, Goldhaber SZ, Schoepf UJ. Clinical validity of a negative computed tomography scan in patients with suspected pulmonary embolism: a systematic review. *JAMA.* 2005;293:2012–2017.
  18. Goldhaber SZ. Echocardiography in the management of pulmonary embolism. *Ann Intern Med.* 2002;136:691–700.
  19. McConnell MV, Solomon SD, Rayan ME, Come PC, Goldhaber SZ, Lee RT. Regional right ventricular dysfunction detected by echocardiography in acute pulmonary embolism. *Am J Cardiol.* 1996;78:469–473.
  20. Kucher N, Rossi E, De Rosa M, Goldhaber SZ. Prognostic role of echocardiography among patients with acute pulmonary embolism and a systolic arterial pressure of 90 mm Hg or higher. *Arch Intern Med.* 2005; 165:1777–1781.
  21. Piazza G, Goldhaber SZ. The acutely decompensated right ventricle: pathways for diagnosis and management. *Chest.* 2005; 128:1836–1852.
  22. van Belle A, Buller HR, Huisman MV, Huisman PM, Kaasjager K, Kamphuisen PW, Kramer MH, Kruip MJ, Kwakkel-van Erp JM, Leebeek FW, Nijkeuter M, Prins MH, Sohne M, Tick LW. Effectiveness of managing suspected pulmonary embolism using an algorithm combining clinical probability, D-dimer testing, and computed tomography. *JAMA.* 2006;295: 172–179.