

---

# CARDIOLOGY PATIENT PAGE

## Diseases of the Veins

Joshua A. Beckman, MD, MS

---

**T**hree sets of vessels comprise the circulatory system: arteries, lymphatics, and veins. Arteries bring oxygen-carrying blood from the heart to the tissues. In the normal course of blood circulation, small amounts of fluid and protein leak from arteries and veins. Lymphatic vessels bring this protein-rich fluid back into the circulation. The third type of blood vessel is the vein.

Veins bring oxygen-depleted blood from the organs and tissues to the heart and lungs, where it is re-oxygenated. Blood return to the heart tends to be passive and is enabled by muscle contraction in the arms and legs. Because the venous system is a low pressure one, the telltale complaints and physical signs of venous disease on which your physician relies for diagnosis are often subtle and sometimes require further testing. Diseases of the veins fall into two broad categories: blockage from a blood clot (thrombosis) and inadequate venous drainage (insufficiency).

### Thrombosis

The legs are the most common location for blood clot formation (thrombus) in the venous system. Today, the most commonly encountered causes for blood clots include cancer, prolonged immobility, an inherited tendency for blood clotting, pregnancy, and contraceptive use.

### Superficial Thrombophlebitis

Blood clots may develop in the veins that lie either just under the skin or deep within the limb. In the skin-deep (superficial) veins, a blood clot commonly appears as a red streak along the course of an affected vein and is often accompanied by inflammation (phlebitis). The vein may feel warm and tender and may be swollen. This combination of clot and inflammation, known as superficial thrombophlebitis, commonly oc-

curs in the setting of varicose veins. Cancer may be the cause for development of many episodes of superficial blood clots; this is known as Trousseau's syndrome.

Superficial thrombophlebitis is typically more annoying than dangerous because the likelihood that the clot(s) will break up and be transported in pieces to the lung is very low. Physicians commonly treat symptoms with leg elevation, moist heat, and nonsteroidal antiinflammatory medications (such as ibuprofen). Rarely, blood clots with persistent symptoms will be treated with a short course of blood thinning medication (anticoagulation).

### Deep Vein Thrombosis

Blood clots in the veins deep within the legs (deep vein thromboses, or DVTs) are more difficult to diagnose because symptoms are present in only 50% of patients. When symptoms are present, patients may complain of pain with walking, typically in the ball of the foot; leg swelling; leg pressure; or leg fullness. DVTs are classified as primary or secondary. Primary DVTs occur in the absence of an obvious cause and are usually caused by an inherited tendency to clotting. Secondary DVTs occur as a result of a specific event, like immobilization after surgery or cancer.

When a clot forms, blood return to the heart is blocked. Smaller, alternate veins (collateral vessels) can return blood back to the heart, but not so efficiently as the central large vein. This back-up increases both pressure within the vein and also fluid leakage from the vein, resulting in leg swelling. The clot itself can cause inflammation, producing warmth, redness, and tenderness. During examination, the doctor may note swelling, fullness of the affected muscles, or feel the cord of clotted blood in the vessel.

Physicians focus treatment on the complication of blood clots. Without treatment, up to one-fourth of all leg DVTs will have a piece of clot detach, travel through the veins, and lodge within the lungs, where it can cause a pulmonary embolism (PE). Complications of a PE are significant shortness of breath, marked exercise limitation, and death. (For a more detailed discussion, see the Cardiology Patient Page by Goldhaber SZ, Morrisson RB. Pulmonary embolism and deep vein thrombosis. *Circulation*. 2002;106:1436–1438.)

---

From the Cardiovascular Division, Brigham and Women's Hospital, Harvard Medical School, Boston, Mass.

Correspondence to Joshua A. Beckman, MD, MS, Cardiovascular Division, Brigham and Women's Hospital, 75 Francis St, Boston, MA 02115. E-mail [jbeckman@partners.org](mailto:jbeckman@partners.org) (*Circulation*. 2002;106:2170-2172.)

© 2002 American Heart Association, Inc.

*Circulation* is available at <http://www.Circulationaha.org>  
DOI: 10.1161/01.CIR.0000036740.75461.80

The diagnosis of DVT is most commonly made with ultrasound. Ultrasound is very reliable for discovering blood clots at or above the knee, the location most likely to send off an embolism. In contrast, the veins below the knee are smaller, the anatomy of the veins commonly varies between people, and the ability of the test to diagnose a DVT is not as high. Only rarely is it necessary to perform more testing, such as magnetic resonance imaging (MRI) or a dye test (a venogram).

To decrease the symptoms of a DVT and prevent the embolization of a fragment to the lungs, physicians will prescribe blood-thinning medication (anticoagulants), first heparin (given intravenously or by injection) and then warfarin (administered by mouth). Anticoagulation dramatically reduces the rate of pulmonary embolism, should be continued for 3 to 6 months, and requires frequent measurement of the level of blood thinning. Appropriate therapy lowers the occurrence of pulmonary embolism from 25% to 5% over the first year but is associated with a small increase (about 2% to 3%) in the risk of significant bleeding.

Two areas of therapy are controversial: (1) use of a clot-dissolving (thrombolytic) agent and (2) use of blood thinners for clots in the calf. Thrombolytic agents carry a much higher risk of bleeding and are typically reserved for severe DVTs that seriously restrict blood flow in the leg arteries. Most physicians will prescribe a blood thinning medication for calf blood clots, although the risk of embolization is lower. Anticoagulation should certainly be provided for patients with a calf DVT and an ongoing cause for clotting, such as cancer or orthopedic surgery. In some circumstances, physicians may opt for a repeat ultrasound 5 to 7 days later, treating only those clots that have changed in appearance.

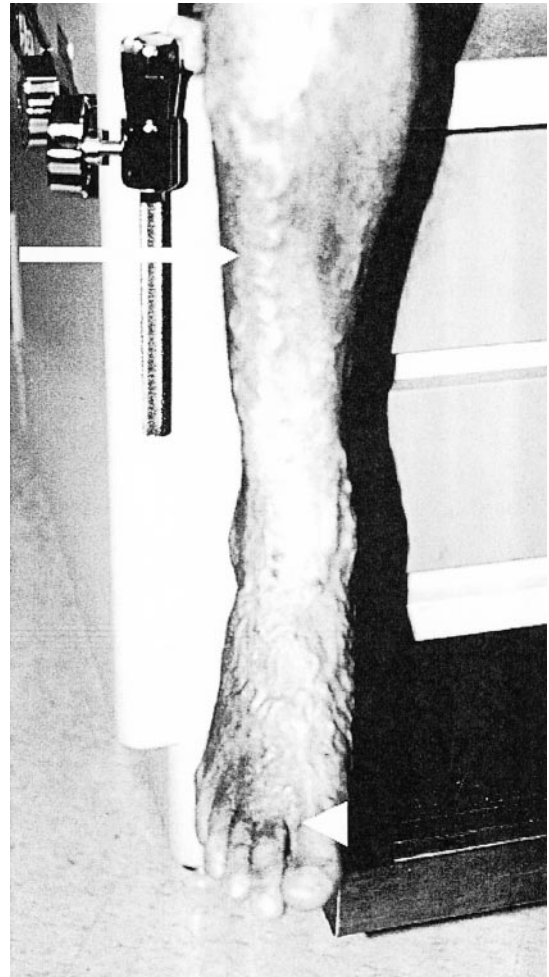### Insufficiency

Resulting from a blood clot or an inherited abnormality of the vein wall, inadequate venous drainage (venous insufficiency) can be classified similarly to thrombosis: superficial (varicose veins) and deep (chronic venous insufficiency).

### Varicose Veins

Superficial venous insufficiency is also known as varicose veins. These are dilated, snake-like segments of veins that lie just below the skin (Figure 1). They are more common in women, and half of all patients being treated will have a family history. In the absence of a blood clot, there is most likely a structural abnormality of the vein wall or valve, allowing backflow of blood and increase in pressure within the vessel. Valves, which prevent backflow of blood, may become damaged, resulting in pooling of blood within the veins. Obesity, pregnancy, prolonged standing, and a sedentary lifestyle may exacerbate dilation of the veins.

Although most patients see a physician for the poor cosmetic appearance of varicose veins, they can also experience symptoms of burning, aching, or itchiness. Symptoms tend to be less severe in the morning after a night of leg elevation in bed and worsen through the day with standing. Occasionally, without proper care, varicose veins may



**Figure 1.** Varicose veins. This photo shows a case of severe varicose veins. The long arrow points to a meandering, snake-like, large varicose vein in the front of the calf. The arrowhead indicates an area of inflammation (redness, warmth) where episodes of bleeding have occurred.

progress and cause skin ulcers, skin infections, blood clots, and spontaneous bleeding.

Standard therapies for varicose veins are exercise, weight loss, blood pressure control, and compression stockings. Compression stockings are specially fit and apply pressure to prevent the veins from being engorged with blood and thus from worsening over time. The stockings should be applied in the morning when the veins are empty. Thus, after washing up in the morning, patients should get back into bed for a few minutes to elevate their legs and thereby drain the veins prior to putting on these stockings. Leg elevation is also helpful; in a reclining position, one should elevate the ankles to the level of the heart or higher. Sitting with legs elevated on a stool or ottoman is not sufficient to drain blood from the veins in the legs. Elevating the foot of the bed is also beneficial. The injection of a scarring agent and surgical removal are rarely needed, but may be used to remove specific varicose veins for cosmetic purposes. However, up to 50% of all patients will develop recurrent varicose veins after removal.

### Chronic Venous Insufficiency

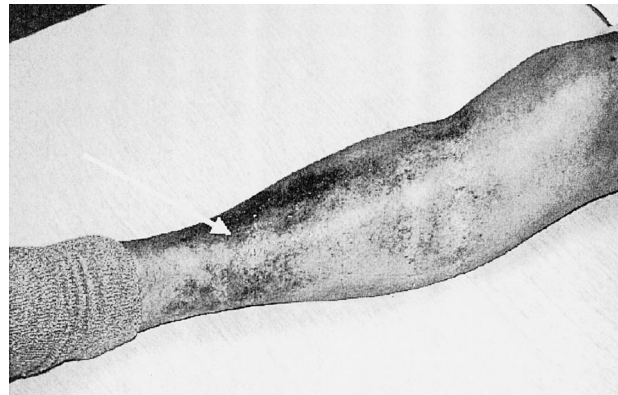
When drainage from the veins deep within the limbs is inadequate over a long period of time, patients develop chronic venous insufficiency. Inadequate venous drainage may occur as a result of obstructed blood flow between the limbs and the heart or because of reflux backward of blood into the veins caused by faulty valves. The most common cause of obstruction is a DVT; other causes are inherited abnormalities and compression of the vein, for example from a tumor or bandage. One third of all patients with DVT will develop chronic venous insufficiency, usually within 5 years. Reflux, or excess flow back into the veins, may occur when the valves in the vein fail, most commonly as a result of clot-related scarring or an inherited valve abnormality.

Chronic venous insufficiency is characterized by leg swelling, pain, darkened skin color, and coarsening skin texture. Gravity is an important factor in the return of blood back to the heart. Swelling is worsened when the leg is below the level of the heart (dependent) and improved after a night of leg elevation in bed. Leg pain, commonly described as heaviness or aching, is usually worse in the warmer weather and during menstruation. Changes in skin color and texture result from deposits of destroyed red blood cells that accumulate over time (Figure 2). Less commonly, patients may report burning, itching, pain, and the development of moist, irregular ulcers around the ankle.

Treatment for venous insufficiency is aimed at improving blood return to the heart and decreasing fluid escape from the veins. Compression stockings, leg elevation, specialized care of ulcers, and the occasional use of diuretics are the main options for therapy. Surgical options are limited and used rarely in this disorder.

### Conclusion

Diseases of the veins are common, relatively easy to treat, and, with treatment, rarely life-threatening. Addressing the



**Figure 2.** Brawny skin changes. This patient has had leg swelling off and on for many years. Notice the reddish-brown skin color changes just above the ankle. These skin changes represent the leakage, destruction, and depositing of red blood cells in the skin. The skin changes are not dangerous but indicate a severe long-term process.

problems of thrombosis and insufficiency should improve physical functioning and quality of life. In the absence of appropriate medical care, patients risk marked disability and life-threatening complications, such as pulmonary embolism. Understanding the nature of these disorders will facilitate therapeutic communication between patient and physician, improving the proper use of appropriate therapies.

### Additional Resources

- Society for Vascular Medicine and Biology. DVT information for patients. Available at: <http://www.svmb.org/patients/dvt.html>. Accessed July 30, 2002.
- American College of Cardiology. Peripheral vascular diseases and you. Available at: <http://www.acc.org/media/patient/PVD/#vascular>. Accessed July 30, 2002.
- Goldhaber SZ, Grasso-Correnti N. Treatment of blood clots. *Circulation*. In press.